Smaller total and subregional cerebellar volumes in posttraumatic stress disorder: a mega-analysis by the ENIGMA-PGC PTSD workgroup

Ashley A. Huggins[1,2], C. Lexi Baird[1,2], Melvin Briggs[1,2], Sarah Laskowitz[1,2], Samar Foudra[1-3], Courtney Haswell[1,2], Delin Sun[1,2,4], Lauren E. Salminen[5], Neda Jahanshad[5], Sophia I. Thomopoulos[5], Dick J. Veltman[6], Jessie L. Frijling[7,8], Miranda Olff[7,9], Mirjam van Zuiden[7], Saskia B.J. Koch[7,10], Laura Nawjin[6,7], Li Wang[11,12], Ye Zhu[11,12], Gen Li[11,13], Dan J. Stein[14], Johnathan Ipser[14], Soraya Seedat[15,16], Stefan du Plessis[15,16], Leigh L. van den Heuvel[15,16], Benjamin Suarez-Jimenez[17], Xi Zhu[18,19], Yoojean Kim[19], Xiaofu He[18,19], Sigal Zilcha-Mano[20], Amit Lazarov[18,21], Yuval Neria[18,19], Jennifer S. Stevens[22], Kerry J. Ressler[22-24], Tanja Jovanovic[22,25], Sanne JH van Rooij[22], Negar Fani[22], Anna R. Hudson[26], Sven C. Mueller[26], Anika Sierk[27], Antje Manthey[27], Henrik Walter[27], Judith K. Daniels[28], Christian Schmahl[29], Julia I. Herzog[29], Pavel Říha[30,31], Ivan Rektor[31], Lauren A.M. Lebois[32,33], Milissa L. Kaufman[32,34], Elizabeth A. Olson[32,33], Justin T. Baker[32,35], Isabelle M. Rosso[32,33], Anthony P. King[36], Isreal Liberzon[37], Mike Angstadt[38], Nicholas D. Davenport[39,40], Scott R. Sponheim[39,40], Seth G. Disner[39,40], Thomas Straube[41], David Hofmann[41], Rongfeng Qi[42], Guang Ming Lu[42], Lee A. Baugh[43-45], Gina L. Forster[43,44,46], Raluca M. Simons[44,47,48], Jeffrey S. Simons[45,47], Vincent A. Magnotta[49], Kelene A. Fercho[43-45,50], Adi Maron-Katz[51], Amit Etkin[51,52], Andrew S. Cotton[53], Erin N. O'Leary[53], Hong Xie[54], Xin Wang[53], Yann Quidé[55,56], Wissam El-Hage[57,58], Shmuel Lissek[59], Hannah Berg[59], Steven Bruce[60], Josh Cisler[61], Marisa Ross[62], Ryan J. Herringa[63], Daniel W. Grupe[64], Jack B. Nitschke[65], Richard J. Davidson[64-66], Christine Larson[67], Terri A. deRoon-Cassini[68,69], Carissa W. Tomas[69,70], Jacklynn M. Fitzgerald[71], Jennifer Urbano Blackford[72,73], Bunmi O. Olatunji[74], William S. Kremen[75,76], Michael J. Lyons[77], Carol E. Franz[75,76], Evan M. Gordon[78], Geoffrey May[79-82], Steven M. Nelson[83,84], Chadi G. Abdallah[85,86], Ifat Levy[87,88], Ilan Harpaz-Rotem[88,89], John H. Krystal[86,88], Emily L. Dennis[90,91], David F. Tate[90,91], David X. Cifu[92], William C. Walker[92,93], Elizabeth A. Wilde[90,91,94], Ian H. Harding[95,96], Rebecca Kerestes[95], Paul M. Thompson[5], Rajendra Morey[1,2]

[1] Brain Imaging and Analysis Center, Duke University, Durham, NC, USA
[2] Department of Veteran Affairs Mid-Atlantic Mental Illness Research, Education and Clinical Center, Durham, NC, USA
[3] Department of Psychiatry & Behavioral Sciences, Duke School of Medicine, Durham, NC, USA
[4] Department of Psychology, The Education University of Hong Kong, Ting Kok, Hong Kong
[5] Imaging Genetics Center, Stevens Neuroimaging & Informatics Institute, Keck School of Medicine of USC, Marina del Rey, CA
[6] Amsterdam UMC Vrije Universiteit, Psychiatry, Amsterdam Neuroscience, Amsterdam, The Netherlands
[7] Amsterdam UMC University of Amsterdam, Psychiatry, Amsterdam Neuroscience, Amsterdam, The Netherlands
[8] Department of Psychiatry, Erasmus University Medical Center, Rotterdam, the Netherlands
[9] ARQ National Psychotrauma Centre, Diemen, The Netherlands
[10] Donders Institute for Brain, Cognition and Behavior, Centre for Cognitive Neuroimaging, Radboud University Nijmegen, Nijmegen, The Netherlands
[11] Laboratory for Traumatic Stress Studies, Chinese Academy of Sciences Key Laboratory of Mental Health, Institute of Psychology, Chinese Academy of Sciences, Beijing, China
[12] Department of Psychology, University of Chinese Academy of Sciences, Beijing, China
[13] Center for Global Health Equity, New York University Shanghai, Shanghai, China
[14] SA MRC Unit on Risk & Resilience in Mental Disorders, Department of Psychiatry and Neuroscience Institute, University of Cape Town, Cape Town, South Africa
[15] Department of Psychiatry, Stellenbosch University, Cape Town, South Africa
[16] South African Medical Research Council Unit on the Genomics of Brain Disorders (GBD), Department of Psychiatry, Stellenbosch University, Stellenbosch, South Africa
[17] Department of Neuroscience, University of Rochester Medical Center, Rochester, NY, USA
[18] Department of Psychiatry, Columbia University Medical Center, New York, NY, USA
[19] New York State Psychiatric Institute, New York, NY, USA
[20] University of Haifa, Haifa, Israel
[21] Tel-Aviv University, Tel Aviv-Yafo, Israel
[22] Department of Psychiatry and Behavioral Sciences, Emory University School of Medicine, Atlanta, GA, USA
[23] Division of Depression and Anxiety Disorders, McLean Hospital, Belmont, MA, USA
[24] Department of Psychiatry, Harvard Medical School, Boston, MA, USA
[25] Department of Psychiatry and Behavioral Neuroscience, Wayne State University School of Medicine, Detroit, MI, USA
[26] Department of Experimental Clinical and Health Psychology, Ghent University, Ghent, Belgium
[27] University Medical Centre Charité, Berlin, Germany
[28] Department of Clinical Psychology, University of Groningen, Groningen, The Netherlands
[29] Department of Psychosomatic Medicine and Psychotherapy, Central Institute of Mental Health, Medical Faculty Mannheim, Heidelberg University, Heidelberg, Germany
[30] First Department of Neurology, St. Anne's University Hospital and Faculty of Medicine, Masaryk University, Brno, Czech Republic
[31] CEITEC-Central European Institute of Technology, Multimodal and Functional Neuroimaging Research Group, Masaryk University, Brno, Czech Republic
[32] Department of Psychiatry, Harvard Medical School, Boston, MA, USA

[33] Center for Depression, Anxiety, and Stress Research, McLean Hospital, Harvard University, Belmont, MA, USA
[34] Division of Women's Mental Health, McLean Hospital, Belmont, MA, USA
[35] Institute for Technology in Psychiatry, McLean Hospital, Belmont, MA, USA
[36] Department of Psychiatry and Behavioral Health, Institute for Behavioral Medicine Research, The Ohio State University, Columbus, OH, USA
[37] Department of Psychiatry, Texas A&M University, Bryan, Texas, USA
[38] Department of Psychiatry, University of Michigan, Ann Arbor, MI, USA
[39] Minneapolis VA Health Care System, Minneapolis, MN, USA
[40] Department of Psychiatry and Behavioral Sciences, University of Minnesota, Minneapolis, MN, USA
[41] Institute of Medical Psychology and Systems Neuroscience, University of Münster, Münster, Germany
[42] Department of Medical Imaging, Jinling Hospital, Medical School of Nanjing University, Nanjing, Jiangsu, China
[43] Division of Basic Biomedical Sciences, Sanford School of Medicine, University of South Dakota, Vermillion, SD, USA
[44] Center for Brain and Behavior Research, University of South Dakota, Vermillion, SD, USA
[45] Sioux Falls VA Health Care System, Sioux Falls, SD, USA
[46] Brain Health Research Centre, Department of Anatomy, University of Otago, Dunedin, New Zealand
[47] Department of Psychology, University of South Dakota, Vermillion, SD, USA
[48] Disaster Mental Health Institute, Vermillion, SD, USA
[49] Departments of Radiology, Psychiatry, and Biomedical Engineering, University of Iowa, Iowa City, IA, USA
[50] Civil Aerospace Medical Institute, US Federal Aviation Administration, Oklahoma City, OK, USA
[51] Department of Psychiatry and Behavioral Sciences, Stanford University, Stanford, CA, USA
[52] VA Palo Alto Health Care System, Palo Alto, CA, USA
[53] Department of Psychiatry, University of Toledo, Toledo, OH, USA
[54] Department of Neurosciences, University of Toledo, Toledo, OH, USA
[55] School of Psychology, University of New South Wales (UNSW) Sydney, Sydney, NSW, Australia
[56] Neuroscience Research Australia, Randwick, NSW, Australia
[57] UMR1253, Université de Tours, Inserm, Tours, France
[58] CIC1415, CHRU de Tours, Inserm, Tours, France
[59] Department of Psychology, University of Minnesota, Minneapolis, MN, USA
[60] Department of Psychological Sciences, Center for Trauma Recovery University of Missouri-St. Louis, St. Louis, MO, USA
[61] Department of Psychiatry, University of Texas at Austin, Austin, TX, USA
[62] Northwestern Neighborhood and Network Initiative, Northwestern University Institute for Policy Research, Evanston, IL, USA
[63] School of Medicine and Public Health, University of Wisconsin Madison, Madison, WI, USA
[64] Center for Healthy Minds, University of Wisconsin-Madison, Madison, WI, USA
[65] Department of Psychiatry, University of Wisconsin-Madison, Madison, WI, USA
[66] Department of Psychology, University of Wisconsin-Madison, Madison, WI, USA
[67] Department of Psychology, University of Wisconsin-Milwaukee, Milwaukee, WI, USA
[68] Division of Trauma and Acute Care Surgery, Department of Surgery, Medical College of Wisconsin, Milwaukee, WI, USA
[69] Comprehensive Injury Center, Medical College of Wisconsin, Milwaukee, WI, USA
[70] Division of Epidemiology and Social Sciences, Institute of Health and Equity, Medical College of Wisconsin Milwaukee, WI, USA
[71] Department of Psychology, Marquette University, Milwaukee, WI, USA
[72] Munroe-Meyer Institute, University of Nebraska Medical Center, Omaha, NE, USA
[73] Department of Psychiatry and Behavioral Sciences, Vanderbilt University Medical Center, Nashville, TN, USA
[74] Department of Psychology, Vanderbilt University, Nashville, TN, USA
[75] Department of Psychiatry, University of California, San Diego, La Jolla, CA, USA
[76] Center for Behavior Genetics of Aging, University of California, San Diego, La Jolla, CA, USA
[77] Dept. of Psychological & Brain Sciences, Boston University, Boston, MA, USA
[78] Department of Radiology, Washington University School of Medicine, St. Louis, MO, USA
[79] Veterans Integrated Service Network-17 Center of Excellence for Research on Returning War Veterans, Waco, TX, USA
[80] Department of Psychology and Neuroscience, Baylor University, Waco, TX, USA
[81] Center for Vital Longevity, School of Behavioral and Brain Sciences, University of Texas at Dallas, Dallas, TX, USA
[82] Department of Psychiatry and Behavioral Science, Texas A&M University Health Science Center, Bryan, TX, USA
[83] Department of Pediatrics, University of Minnesota, Minneapolis, MN, USA
[84] Masonic Institute for the Developing Brain, Minneapolis, MN, USA
[85] Department of Psychiatry, Baylor College of Medicine, Houston, TX, USA
[86] Department of Psychiatry, Yale University School of Medicine, New Haven, CT, USA
[87] Departments of Comparative Medicine, Neuroscience and Psychology, Wu Tsai Institute, Yale University, New Haven, CT, USA
[88] Division of Clinical Neuroscience, National Center for PTSD, West Haven, CT, USA
[89] Departments of Psychiatry and of Psychology, Wu Tsai Institute, Yale University, New Haven, CT, USA
[90] Department of Neurology, University of Utah School of Medicine, Salt Lake City, UT, USA
[91] George E. Wahlen Veterans Affairs Medical Center, Salt Lake City, UT, USA
[92] Department of Physical Medicine and Rehabilitation, Virginia Commonwealth University, Richmond, VA, USA
[93] Veterans Affairs (VA) Richmond Health Care, Richmond, VA, USA
[94] H. Ben Taub Department of Physical Medicine and Rehabilitation, Baylor College of Medicine, Houston, TX, USA
[95] Department of Neuroscience, Central Clinical School, Monash University, Melbourne, Victoria, Australia
[96] Monash Biomedical Imaging, Monash University, Melbourne, Victoria, Australia

Abstract

Background: The cerebellum critically contributes to higher-order cognitive and emotional functions such fear learning and memory. Prior research on cerebellar volume in PTSD is scant and has neglected neuroanatomical subdivisions of the cerebellum that differentially map on to motor, cognitive, and affective functions.

Methods: We quantified cerebellar lobule volumes using structural magnetic resonance imaging in 4,215 adults (PTSD n= 1640; Control n=2575) across 40 sites from the from the ENIGMA-PGC PTSD working group. Using a new state-of-the-art deep-learning based approach for automatic cerebellar parcellation, we obtained volumetric estimates for the total cerebellum and 28 subregions. Linear mixed effects models controlling for age, gender, intracranial volume, and site were used to compare cerebellum total and subregional volume in PTSD compared to healthy controls. The Benjamini-Hochberg procedure was used to control the false discovery rate ($p_{\text{-FDR}} < .05$).

Results: PTSD was associated with significant grey and white matter reductions of the cerebellum. Compared to controls, people with PTSD demonstrated smaller total cerebellum volume. In addition, people with PTSD showed reduced volume in subregions primarily within the posterior lobe (lobule VIIB, crus II), but also the vermis (VI, VIII), flocculonodular lobe (lobule X), and cerebellar white matter (all $p_{\text{-FDR}} < 0.05$). Effects of PTSD on volume were consistent, and generally more robust, when examining symptom severity rather than diagnostic status.

Conclusions: These findings implicate regionally specific cerebellar volumetric differences in the pathophysiology of PTSD. The cerebellum appears to play an important role in high-order cognitive and emotional processes, far beyond its historical association with vestibulomotor function. Further examination of the cerebellum in trauma-related psychopathology will help to clarify how cerebellar structure and function may disrupt cognitive and affective processes at the center of translational models for PTSD.

Keywords: *PTSD, cerebellum, structural MRI, volume*

Introduction

Exposure to trauma is common, and nearly 10% of trauma survivors develop chronic symptoms of posttraumatic stress disorder (PTSD; (1)), a debilitating psychiatric condition characterized by a constellation of symptoms including intrusive memories, avoidance, hypervigilance, and negative changes in mood and cognition (2). An extensive body of research has illuminated key brain regions that differentiate PTSD patients from trauma-exposed controls (3-5). Notably, PTSD has been consistently linked to smaller volume of brain regions including the hippocampus (6-9), ventromedial prefrontal cortex (vmPFC; (10-12)), amygdala (13-15), insula (16-18), and anterior cingulate cortex (ACC; (9, 19, 20)). These regions are part of a critical neural circuit supporting diverse cognitive and affective functions that are disrupted in PTSD, including threat processing, emotion regulation, and emotional memory(21, 22).

Relatively little attention has been paid to areas of the brain outside these canonical regions. Notably, research emerging over the past three decades clearly demonstrates that the cerebellum contributes immensely to higher-order cognition and emotion (23-25). Historically known for its central role in the vestibulomotor system (26), the human cerebellum has rapidly (and disproportionately) evolved over time (27-29). Despite being approximately 10% of the brain's overall size (30), the cerebellum houses the vast majority of the brain's total neurons (31) and occupies nearly 80% of the neocortical surface area (29). The cerebellum shares rich anatomical connections with much of the brain, including with prefrontal and limbic areas (27, 32-34), strongly suggesting that it participates in processes beyond motor coordination that may be highly relevant to PTSD. Moreover, the cerebellum's widespread connectivity with stress-related regions (such as with the amygdala, hippocampus, and periaqueductal gray) may make it especially vulnerable to traumatic stress, potentially leading to the development of PTSD symptoms by disrupting typical brain-mediated stress responses via cerebro-cerebellar circuits (35, 36). Recent studies have also demonstrated that the cerebellum is involved in fear learning and memory (37-40); considering PTSD is characterized by aberrancies in threat detection and processing (41, 42), this accumulating evidence makes a compelling case that the cerebellum is involved in the pathophysiology of PTSD.

A growing body of structural and functional magnetic resonance imaging studies provide evidence of altered cerebellar volume and function in PTSD (37). Specifically, smaller cerebellar volume has been observed in both adult (43, 44) and pediatric (45, 46) PTSD samples. PTSD has also been linked to disrupted functional connectivity between the cerebellum and key cognitive and affective regions, including the amygdala (47). Although meta-analytic work has suggested cerebellar activation differentiates PTSD patients from healthy controls (48-50), other studies have failed to observe any cerebellar volumetric differences related to PTSD (51-53), necessitating additional studies to resolve these discrepant findings. Collectively, these results highlight the importance of incorporating the cerebellum into well-established translational models of PTSD.

Prior research on cerebellar volume in PTSD has been limited by largely neglecting to consider important neuroanatomical subdivisions of the cerebellum that differentially map onto motor, cognitive, and affective functions. Gross anatomy delineates two major fissures dividing the cerebellum into three anatomical divisions: the anterior (lobules I-V), posterior (lobules VI-IX), and flocculonodular (lobule X) lobes (54). The anterior lobe receives spinal afferents via spinocerebellar tracts and shares reciprocal connections with motor cortices to help support motor movements, gait, and equilibrium (55). By contrast, extensive non-motor functions have been identified within the evolutionarily newer posterior cerebellum (56), which lacks spinal cord inputs and has connections with cortical areas integral to higher order processes, including the prefrontal cortex and cingulate gyrus (57, 58). Activation within the posterior lobe has been observed during language and verbal working memory (lobule VI, crus I), spatial processing (lobule VI), and executive function (lobule VI and VIIB, crus I) tasks (24, 56, 59). Aversive stimulus processing, such as noxious heat and unpleasant images, also appears to involve the posterior cerebellum (lobules VI and VIIB and crus I), implicating these regions in defensive responding (60). The vermis - the medial cortico-nuclear column connecting the left and right cerebellar hemispheres - is considered an extension of the Papez emotion circuit (61) and is activated during affective processing

(23, 25, 62). Vermal lobules also interact with other regions critical for emotional associative learning including the amygdala, hypothalamus, and periaqueductal gray (23, 63, 64). Taken together, these careful studies on functional topography have identified three broad subdivisions of the cerebellum comprising sensorimotor, cognitive, and limbic areas (24).

As a heterogenous disorder linked to dysfunction within multiple cerebellum-supported processes, it is unclear whether structural differences in the cerebellum in PTSD are global or may be localized to specific subregions. Indeed, prior work has identified differences in cerebellar volume and function distributed across the cerebellum, including within the vermis (43, 46), crus (44, 65), and lobules VI and VII (66-68). Yet, these diffuse subregional findings are often not replicated, contributing to a lack of consensus regarding the cerebellum's role in PTSD. Importantly, better understanding the relevance of cerebellar structure in the pathophysiology of PTSD may help elucidate potential mechanisms that perpetuate chronic symptoms of PTSD and aid in our ability to develop targeted, effective interventions.

To this end, the present study employed a mega-analysis of total and subregional cerebellar volumes in a large, multi-cohort dataset from the Enhancing NeuroImaging Genetics through Meta-Analysis (ENIGMA)-Psychiatric Genomics Consortium (PGC) PTSD workgroup. By contrast with a meta-analysis, a mega-analysis centralizes and pools data from multiple sites and fits statistical models to the aggregated data while adjusting for site effects. We used a novel, standardized ENIGMA cerebellum parcellation protocol (Kerestes et al., 2022) to quantify cerebellar lobule volumes using structural MRI data from 4,215 adults with (n=1,640) and without (n=2,575) PTSD. We examined the effects of PTSD on cerebellar volumes, adjusting for age, gender, and total intracranial volume. Based on prior work (43-46), we hypothesized that PTSD would be associated with smaller total cerebellum volume. Considering functional topography indicates the 'limbic' and 'cognitive' cerebellum localize to the vermis and posterior lobes, respectively, we hypothesized PTSD would be associated with smaller volumes within these two anatomical divisions (23-25).

Methods and Materials

Sample.
Clinical, demographic, and neuroimaging data from the ENIGMA-PGC PTSD working group included in the current study are presented in Table 1. MRI scans from 4,215 subjects, including 1640 PTSD patients and 2,575 healthy controls (trauma-exposed or naïve), were automatically segmented into cerebellar subregions. All study procedures were approved by local institutional review boards (IRB), and participants provided written informed consent. The present analyses were granted exempt status by the Duke University Health System IRB.

Table 1. *Sample characteristics by site.*

	N	**Age**	**Gender**		**Diagnosis**		**Diagnostic Tool**	**Sample**	**PTSD Severity**	**Severity Tool**
Site		*M (SD)*	*F*	*M*	*PTSD*	*Ctrl*			*M % (SD)*	
ADNI DoD	103	68.53 (4.05)	2	101	43	60	CAPS-IV	Military	21.00 (20.71)	CAPS-IV
Amsterdam AMC	73	40.01 (9.97)	34	39	36	37	CAPS-IV	Police	26.37 (24.57)	CAPS-IV
Beijing	87	48.49 (10.29)	53	34	41	46	PCL-5	Civilian	35.52 (20.00)	PCL-5
Cape Town	106	26.78 (6.39)	106	0	6	100	CAPS-IV	Civilian	46.14 (21.74)	CAPS-IV
Columbia	151	34.96 (10.65)	90	61	72	79	CAPS-IV, SCID	Civilian	34.07 (26.55)	CAPS-IV, CAPS-5
Duke	376	39.24 (10.02)	72	304	111	265	CAPS-IV, CAPS-5, SCID	Military	20.04 (23.44)	CAPS-IV, CAPS-5, DTS
Emory GTP	59	40.24 (11.97)	59	0	13	46	CAPS-IV	Civilian	21.04 (16.31)	CAPS-IV

Ghent	65	37.15 (12.22)	65	0	8	57	MINI	Civilian	---	---
Groningen	37	38.81 (9.46)	37	0	37	0	CAPS-IV	Civilian	49.24 (9.63)	CAPS-IV
LIMBIC-CENC	1045	40.10 (9.84)	144	901	354	691	PCL-5	Military	32.12 (23.73)	PCL-5
Mannheim	40	35.83 (11.50)	40	0	40	0	SCID	Civilian	53.95 (22.26)	DTS
Masaryk	269	51.72 (18.67)	166	103	109	160	PCL-C	Civilian	34.59 (12.00)	PCL-C
McLean 1	78	34.56 (12.49)	78	0	51	27	CAPS-5	Civilian	42.85 (31.99)	CAPS-5
McLean 2	94	34.15 (8.89)	52	42	21	73	CAPS-IV	Civilian	---	CAPS-IV
Michigan	62	30.42 (7.71)	0	62	40	22	CAPS-IV	Military, Civilian	35.92 (25.10)	CAPS-IV
Milwaukee	70	32.48 (10.05)	35	35	19	51	CAPS-5	Civilian	17.45 (15.34)	CAPS-5
Minnesota	62	42.85 (9.51)	5	57	12	50	CAPS-IV	Military	13.54 (14.39)	CAPS-IV
Missouri	64	32.02 (9.73)	64	0	57	7	CAPS-IV	Civilian	---	---
Münster	43	26.41 (6.85)	38	5	19	24	SCID	Civilian	---	---
Nanjing	132	57.23 (5.94)	73	59	48	84	SCID	Civilian	20.83 (13.44)	CAPS-IV
South Dakota	114	29.29 (10.44)	21	93	71	43	PCL-C, PCL-M	Military	44.67 (18.56)	PCL-C, PCL-M
Stanford	146	33.59 (10.44)	67	78	73	73	CAPS-IV	Military, Civilian	26.57 (23.64)	CAPS-IV
Toledo	77	35.38 (11.40)	35	42	15	62	CAPS-IV	Military, Civilian	17.49 (18.42)	CAPS-IV
Tours	39	28.23 (9.88)	39	0	9	30	CAPS-IV	Civilian	31.11 (14.41)	CAPS-IV
Wisconsin 1	104	33.00 (8.25)	104	0	83	21	CAPS-5, SCID	Civilian	47.26 (24.62)	PCL-5, PCL-C
Wisconsin 2	24	29.96 (5.52)	3	21	12	12	CAPS-IV	Military	25.77 (24.68)	CAPS-IV
VA Minneapolis	241	32.64 (7.80)	13	226	91	150	CAPS-IV	Military	29.40 (19.16)	CAPS-IV
VA Waco	91	39.75 (11.02)	11	80	63	29	PCL-5	Military	54.10 (26.21)	PCL-5
VA West Haven	55	33.55 (8.77)	6	49	32	23	CAPS-IV	Military	34.16 (21.94)	CAPS-IV
Vanderbilt	46	31.24 (4.64)	9	37	12	34	CAPS-5	Military	10.76 (14.49)	CAPS-5
VETSA	190	61.79 (2.66)	0	190	19	171	PCL-C	Military	28.89 (11.24)	PCL-C
Yale	69	29.61 (7.65)	11	58	31	23	CAPS-IV	Military	20.69 (20.97)	CAPS-IV
Overall	**4215**	**40.08 (13.72)**	**1532**	**2677**	**1640**	**2575**	**---**	**---**	**30.53 (23.12)**	**---**

Note: CAPS-IV, Clinician Administered PTSD Scale for DSM-IV; CAPS-5, Clinician Administered PTSD Scale for DSM-5; DTS, Davidson Trauma Scale for DSM-IV; MINI, Mini Neuropsychiatric Interview; PCL-C, PTSD Checklist-Civilian Version; PCL-M, PTSD Checklist-Military Version; PCL-5, PTSD Checklist for DSM-5; SCID, Structured Clinical Interview for DSM

Image acquisition and processing.
Whole-brain T1-weighted anatomical MR images were collected from each participant. Acquisition parameters for each cohort are detailed in Supplementary Table S2. Segmentation and quality control procedures were performed at Duke University. A subset of the data (n=1,045) from the Long-Term Impact of Military-Relevant Brain Injury Consortium-Chronic Effects of Neurotrauma Consortium (LIMBIC-CENC) were processed at University of Utah. Cerebellar parcellation was carried out using a deep-learning algorithm, Automatic Cerebellum Anatomical Parcellation using U-Net with Locally

Constrained Optimization (ACAPULCO) (69). Images were corrected for intensity inhomogeneity using N4, blurred with a 3D Gaussian kernel (SD=3mm), and transformed to MNI template space. ACAPULCO then employed a cascade of two convolutional neural networks to first define a 3D-bounding box around the cerebellum and then divide it into anatomically meaningful regions. This ultimately resulted in volumetric estimates for the total cerebellum and 28 subregions, including the hemispheric anterior (lobules I-III, IV, and V), posterior (lobules VI, VIIB, VIIIA, VIIIB, IX, and crus I-II), and flocculonodular (lobule X) lobes, vermal lobules VI, VII, VIII, IX, and X, and the corpus medullare (the white matter core of the cerebellum). ACAPULCO achieves results comparable to other established cerebellum parcellation protocols (e.g., CERES2), but may perform better for multi-site datasets (69).

Following segmentation, a two-step quality control procedure was employed, consisting of (1) removal of statistical outliers $\pm$ 2.689 SD from the site mean, and (2) visual inspection of cerebellar parcels. Each subject's segmentation was visually inspected and scored by a minimum of two trained raters (AH, SL, MB, LB) on a scale from 1 (good) to 3 (poor/failed). In the event of a discrepancy between raters, the parcellation was examined by a third rater for consensus. Segments were considered individually; therefore, select subregional volumes (e.g., statistical outliers, circumscribed segmentation errors) were excluded, while the remainder of segments were retained for analysis if correct. Subjects who scored 3 were excluded from all analyses. Breakdown of ratings by site are noted in Supplementary Table S3.

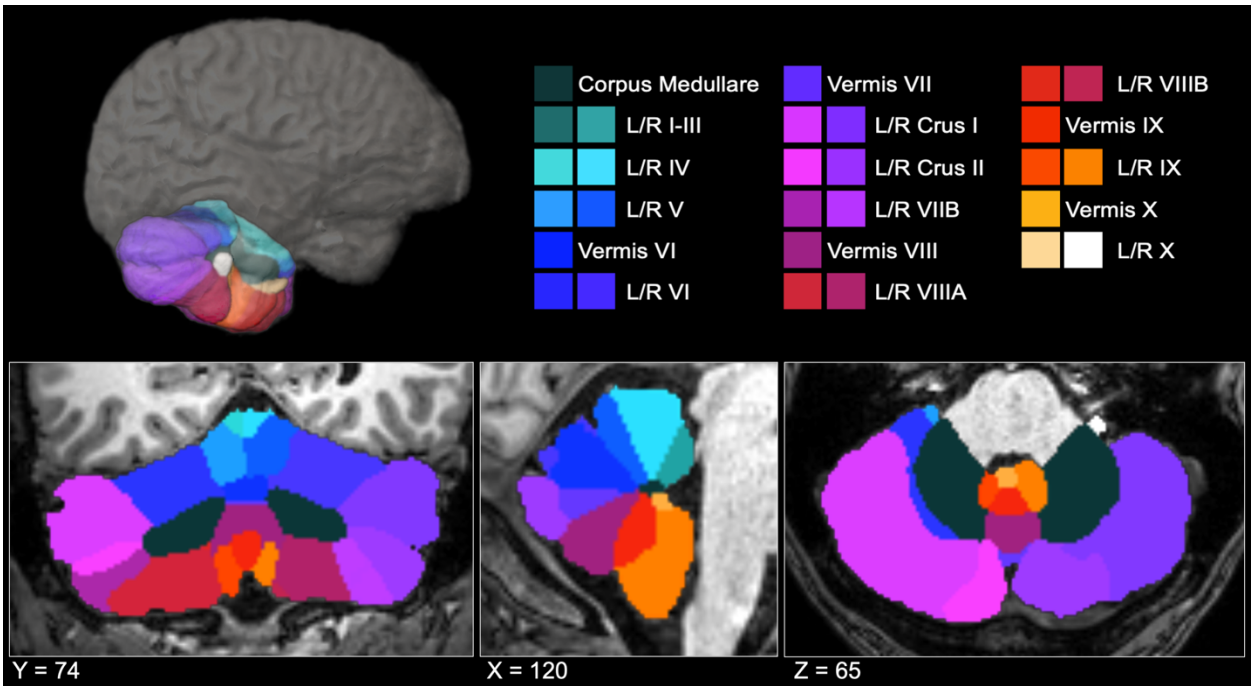

Figure 1. ACAPULCO cerebellum parcellation for a representative subject in three-dimensional (upper left), coronal (left), sagittal (middle), and axial (right) views. L, left; R, right.

Statistical analysis.

To examine whether PTSD diagnosis was associated with volume differences in the grey matter volumes of the whole cerebellum, hemispheric subregions, vermis, and cerebellar white matter, we fit a series of linear mixed effects models were performed. Statistical analyses were conducted using the *lmer* package (70) in R v4.1.3. In each model, age, gender, and total intracranial volume were treated as fixed effects, and site was treated as a random effect. The Benjamini-Hochberg procedure (71) was used to adjust significance values to control the false discovery rate ($p_{\text{-FDR}} < .05$). Cohen's *d* was calculated as a measure of effect size. Models were repeated implementing PTSD severity – rather than diagnosis – as a continuous predictor. Due to site measurement differences, PTSD severity was quantified as a percentage of the total score possible (see Table 1).

Given frequent co-occurrence of PTSD and likely independent effects on cerebellum volume, secondary analyses were conducted to examine the potential effects of depression (72, 73), alcohol use disorder (74, 75), and childhood trauma (76, 77) on cerebellar volumes. For sites with available covariate data (see Supplemental Material), an additional series of linear mixed effects models were conducted, including fixed effects of (1) major depressive disorder diagnosis, (2) alcohol use disorder diagnosis, and (3) total score on the Childhood Trauma Questionnaire (CTQ; (78)).

Results

Associations between PTSD diagnosis and cerebellum volumes. Effects of PTSD diagnosis on cerebellum volumes are presented in Table 2. Consistent with hypotheses, after adjusting for age, gender, and total intracranial volume, PTSD diagnosis was associated with significantly smaller total cerebellar volume, b = -976.90, t = -2.779, $p_{\text{-FDR}}$ = 0.005. PTSD diagnosis was also associated with smaller volume of the corpus medullare, b = -157.47, t = -2.234, $p_{\text{-FDR}}$ = 0.026.

Within the anterior cerebellum (lobules I-V), PTSD diagnosis was associated with smaller volume of right lobule V, b = -44.040, t = -2.541, $p_{\text{-FDR}}$ = 0.036.

Within the posterior cerebellum (crus, lobules VI-IX), PTSD diagnosis was associated with smaller volume of left crus II, b = -111.602, t = -2.678, $p_{\text{-FDR}}$ = 0.028, left lobule VIIB, b = -122.22, t = -3.478, $p_{\text{-FDR}}$ =.004, and right lobule VIIB, b = -137.74, t = -3.663, $p_{\text{-FDR}}$ = 0.001.

No significant effects of PTSD diagnosis were observed on volumes within the flocculonodular lobe (lobule X). There was an effect of PTSD on left lobule X volume, but this did not survive multiple comparisons corrections ($p_{\text{-FDR}}$ = 0.052).

There was a significant effect of PTSD diagnosis on volumes of vermal lobules VI, b = -20.790, t = -2.684, $p_{\text{-FDR}}$ = 0.018, and VIII, b = -28.649, t = -2.703, $p_{\text{-FDR}}$ = 0.007. There were no other significant effects of PTSD within the vermis.

***Table 2**: Effects of PTSD diagnosis on cerebellum volume.*

ROI	N	*b*	*SE*	*t*	*p-FDR*	*d*
			Anterior			
Left I-III	4185	-8.780	6.576	-1.335	0.546	-0.041
Left IV	4164	-16.152	17.77	-0.909	0.546	-0.028
Left V	4119	14.472	15.948	0.907	0.365	0.028
Right I-III	4186	-5.663	6.924	-0.818	0.621	-0.025
Right IV	4162	-5.196	18.644	-0.279	0.781	-0.009
Right V	**4114**	**-44.040**	**17.33**	**-2.541**	**0.036***	**-0.080**
			Posterior			
Left Crus I	3979	-28.24	63.46	-0.445	0.767	-0.014
Left Crus II	**4112**	**-111.602**	**41.67**	**-2.678**	**0.028***	**-0.084**
Left VI	4165	-2.681	42.062	-0.064	0.949	-0.002
Left VIIB	**4098**	**-122.22**	**35.14**	**-3.478**	**0.004****	**-0.109**
Left VIIIA	4037	-18.93	35.49	-0.534	0.832	-0.017
Left VIIIB	3897	-37.84	21.54	-1.757	0.166	-0.056
Left IX	4037	-20.26	20.80	-0.974	0.578	-0.032
Right Crus I	4109	-93.41	62.50	-1.494	0.315	-0.047
Right Crus II	4164	-77.101	44.34	-1.739	0.287	-0.054
Right VI	4175	35.54	43.57	0.816	0.484	0.025
Right VIIB	**4029**	**-137.74**	**37.60**	**-3.663**	**0.001*****	**-0.115**
Right VIIIA	3814	-29.42	32.32	-0.910	0.635	-0.030
Right VIIIB	3856	-14.00	21.96	-0.638	0.524	-0.021
Right IX	4044	-17.64	21.19	-0.832	0.567	-0.028
			Flocculonodular			

Left X	4176	-6.407	2.881	-2.224	0.052	-0.069
Right X	4175	-3.868	2.954	-1.309	0.191	-0.041
			Vermis			
Vermis VI	**4187**	**-20.790**	**7.746**	**-2.684**	**0.018***	**-0.084**
Vermis VII	4189	-3.419	5.704	-0.599	0.549	-0.019
Vermis VIII	**4191**	**-28.649**	**10.599**	**-2.703**	**0.007****	**-0.084**
Vermis IX	4186	-13.816	10.412	-1.327	0.185	-0.045
Vermis X	4175	-3.143	1.940	-1.620	0.175	-0.052
Total Volume	**4192**	**-976.9**	**351.6**	**-2.779**	**0.005****	**-0.086**
Corpus Medullare	**4162**	**-157.47**	**70.48**	**-2.234**	**0.026***	**-0.069**

*** $p_{\text{-}FDR} < 0.001$, ** $p_{\text{-}FDR} < 0.01$, * $p_{\text{-}FDR} < .05$

PTSD severity.

When examining PTSD symptom severity (rather than diagnostic status), results were similar, if generally more robust (see Table 3). Specifically, PTSD symptom severity was associated with significantly smaller total cerebellum volume, b = -682.00, t = -3.688, $p_{\text{-FDR}}$ = 0.0002, and corpus medullare volumes, b = -112.75, t = -3.030, $p_{\text{-FDR}}$ = 0.0002. Effects were consistent across the posterior cerebellum and vermis, with significant effects of PTSD symptom severity on volumes of left crus II, b = -64.30, t = -2.943 $p_{\text{-FDR}}$ = 0.011, left lobule VIIB, b = -64.83, t = -3.529, $p_{\text{-FDR}}$ = 0.003, right lobule VIIB, b = -77.51, t = -3.903, $p_{\text{-FDR}}$ = 0.0007, and vermal lobules VI, b = -14.464, t = -3.554, $p_{\text{-FDR}}$ = 0.002, and VIII, b = -17.150, t = -3.061, $p_{\text{-FDR}}$ = 0.006.

By contrast, the significant effect of PTSD on volume of right lobule V was no longer significant when examining symptom severity instead of diagnosis ($p_{\text{-FDR}}$ = 0.060). Additionally, PTSD symptom severity was associated with significantly smaller volume of the flocculonodular cerebellum, with effects observed in both hemispheres of lobule X (left: b = -3.606, t = -2.361, $p_{\text{-FDR}}$ = 0.018; right: b = -4.507, t = -2.881, $p_{\text{-FDR}}$ = 0.008).

***Table 3**: Effects of PTSD severity on cerebellar volumes.*

ROI	N	*b*	*SE*	*t*	*p-FDR*	*d*
			Anterior			
Left I-III	3757	-5.818	3.450	-1.686	0.276	-0.055
Left IV	3731	-9.481	9.305	-1.019	0.462	-0.033
Left V	3688	-4.207	8.310	-0.506	0.613	-0.017
Right I-III	3756	-3.565	3.628	-0.983	0.489	-0.032
Right IV	3733	-3.532	9.740	-0.363	0.717	-0.012
Right V	3685	-21.279	9.169	-2.321	0.060	-0.078
			Posterior			
Left Crus I	3555	-11.17	33.37	-0.335	0.861	-0.011
Left Crus II	**3681**	**-64.30**	**21.85**	**-2.943**	**0.011***	**-0.097**
Left VI	3736	-6.793	22.091	-0.307	0.758	-0.010
Left VIIB	**3667**	**-64.83**	**18.37**	**-3.529**	**0.003****	**-0.117**
Left VIIIA	3606	-28.31	18.83	-1.503	0.233	-0.050
Left VIIIB	3478	-18.45	11.45	-1.612	0.250	-0.055
Left IX	3608	-14.84	10.93	-1.358	0.245	-0.047
Right Crus I	3678	-53.11	32.83	-1.617	0.186	-0.053
Right Crus II	3733	-52.86	23.42	-2.257	0.084	-0.074
Right VI	3742	-11.92	23.08	-0.516	0.606	-0.017
Right VIIB	**3595**	**-77.51**	**19.86**	**-3.903**	**<0.001*****	**-0.130**
Right VIIIA	3386	-32.00	17.22	-1.858	0.147	-0.064
Right VIIIB	3434	-6.575	11.762	-0.559	0.672	-0.019
Right IX	3618	-13.20	11.08	-1.191	0.328	-0.044
			Flocculonodular			
Left X	**3742**	**-3.606**	**1.528**	**-2.361**	**0.018***	**-0.077**
Right X	**3741**	**-4.507**	**1.564**	**-2.881**	**0.008****	**-0.094**
			Vermis			
Vermis VI	**3755**	**-14.464**	**4.069**	**-3.554**	**0.002****	**-0.117**
Vermis VII	3756	-5.019	3.002	-1.672	0.118	-0.055
Vermis VIII	**3759**	**-17.150**	**5.603**	**-3.061**	**0.006****	**-0.102**

Vermis IX	3754	-7.908	5.659	-1.397	0.162	-0.052
Vermis X	3743	-1.915	1.014	-1.691	0.152	-0.059
Total Volume	**3758**	**-682.0**	**184.9**	**-3.688**	**<0.001*** **	**-0.120**
Corpus Medullare	**3728**	**-112.75**	**37.21**	**-3.030**	**<0.001*** **	**-0.100**

*** $p_{\text{-FDR}} < 0.001$, ** $p_{\text{-FDR}} < 0.01$, * $p_{\text{-FDR}} < .05$

Potential confounding variables.

When including covariates assessing depression, alcohol use, and childhood trauma, effects of PTSD on cerebellar volumes were somewhat diminished (See Supplemental Material). Yet, detecting significant effects in these additional analyses presented a challenge to statistical power. There was high collinearity between PTSD and covariates, and - in the case of alcohol use disorder and childhood trauma severity - substantially reduced sample size because not all sites reported these variables. In cases where the effect of PTSD diagnosis was non-significant upon inclusion of covariates, we followed up by testing whether depression, alcohol use, or childhood trauma predicted cerebellar volumes on their own; in *no* instance were covariates found to independently predict cerebellar volumes when PTSD status was excluded from the model, demonstrating that our initial findings were specific to PTSD.

Depression status was available for the majority of subjects (n=3978). When adjusting for major depressive disorder diagnosis, PTSD diagnosis remained significantly associated with smaller volume of both left and right lobule VIIB, and vermis VI. While initially significant, effects of PTSD diagnosis on right lobule V ($p_{\text{-FDR}} = 0.096$) and left crus II ($p_{\text{-FDR}} = 0.133$) volumes did not survive correction for multiple comparisons. PTSD symptom severity was associated with smaller total cerebellum and vermis VIII volumes. Uniquely, depression diagnosis was associated with smaller volume of right lobule X, $b = -8.282$, $t = -2.356$, $p_{\text{-FDR}} = 0.038$.

When adjusting for alcohol use disorder, PTSD was associated with significantly smaller volume of vermal lobule VI. Effects of PTSD diagnosis ($p_{\text{-FDR}} = 0.151$) and symptom severity ($p_{\text{-FDR}} = 0.087$) on total cerebellar volume did not reach significance when including alcohol use disorder in the model. Including CTQ severity as a covariate resulted in null effects of PTSD diagnosis; significant effects in left lobule VIIB ($p_{\text{-FDR}} = 0.133$) and vermal lobule VI ($p_{\text{-FDR}} = 0.075$) were no longer significant after correction for multiple comparisons. PTSD symptom severity, however, was significantly associated with vermal lobule VI ($p_{\text{-FDR}} = 0.022$) and total cerebellar ($p_{\text{-FDR}} = 0.036$) volume after adjusting for childhood trauma.

Discussion

Leveraging an international, multisite dataset from ENIGMA-PGC PTSD, we conducted a mega-analysis of total and subregional cerebellar volume in PTSD. Consistent with hypotheses based on published work (43-46), PTSD was associated with smaller total cerebellar volume. We found subregional specificity linking PTSD to smaller volumes in the posterior cerebellum, vermis, and flocculonodular cerebellum. Effects of PTSD on cerebellum volume were consistent (and generally more robust) when examining symptom severity rather than diagnostic status. Overall, these findings contribute to an emerging literature that underscores the relevance of cerebellar structure in the pathophysiology of PTSD. Although the appreciation of the cerebellum for its contributions to cognitive and affective function is relatively recent, the current results bolster a growing literature confirming the cerebellum is not exclusively devoted to motor function and may, in fact, have unique relevance to psychiatric conditions including PTSD (34, 37, 79).

Multiple neuroimaging studies have suggested that altered structure and function of the posterior cerebellum may be a neural correlate of PTSD. For instance, structural differences in lobules VIIB, VIIIA, and VIIIB were found in combat-exposed veterans with PTSD (68). Functionally, PTSD has been linked to increased activation during attentional and emotional tasks (66, 67) and decreased resting-state amplitude of low-frequency fluctuation (80) in lobule VI. In a sample of sexual assault survivors, PTSD severity was negatively associated with activation in lobules VI, VIII, IX, and crus I during the performance of an emotional go/no-go task, and positively associated with activation in left cerebellar

lobules VII-IX and crus I-II when retrieving positive memory during a mental imagery task (81). PTSD has also been linked to decreased global connectivity within the posterior cerebellum during symptom provocation (82). As the most phylogenetically recent part of the cerebellum (27), the posterior lobe is intricately linked with paralimbic and association cortical areas and plays an integral role in the integration of perception, emotion, and behavior (24, 25). Accordingly, the posterior cerebellum contributes to the salience network (lobules VI and VII; (23, 83)) and diverse cognitive-affective processes including working memory, attentional allocation, and associative learning (24, 84). In the context of the current findings, smaller volume of lobule VIIB and crus II may be implicated in the pathophysiology of PTSD, perhaps mapping directly onto symptoms such as hypervigilance and concentration difficulties.

In the present study, PTSD was also associated with smaller volume of vermal lobules VI and VIII. The cerebellar vermis is considered part of the 'limbic' cerebellum and appears to play a key role in emotional processing, learning, and memory (23, 25, 62). Prior work has demonstrated that PTSD is associated with smaller volume (43, 46) and increased signal variability (85) of the vermis. Importantly, structural abnormalities in the vermis may provide increased spatial specificity within existing translational models of PTSD, as converging evidence from both animals and human subjects has shown vermal activation is important for both acquisition (86-89) and extinction (90, 91) of conditioned fear. The cerebellar vermis has strong connections to brain regions (including the brainstem, amygdala, and hypothalamus) that regulate critical survival functions (92). The vermis may contribute to fear learning via threat-associated autonomic changes facilitating defensive behavior, such as increases in respiration, heart rate, and blood pressure (88). Animal research highlights mechanistic links between vermal-midbrain connectivity and defensive behavior; in rats, for instance, lesions of the pathway between the periaqueductal gray and vermal lobule VIII provoke fear-evoked freezing behavior (93). Importantly, vermal connectivity is also implicated in clinical human samples, and PTSD is associated with disrupted resting-state functional connectivity from the vermis to amygdala, periaqueductal gray, and ventromedial prefrontal cortex (94).

Curiously, PTSD symptom severity was associated with reduced volume of bilateral lobule X (which comprises the flocculonodular lobe), but its association with PTSD diagnosis was non-significant. The flocculonodular lobe is primarily implicated in ocular tracking and regulation of the vestibular system (95). Yet, when depression diagnosis was added to the model, there was a significant negative effect of depression on right lobule X, whereas effects of PTSD were non-significant. Structural differences in lobule X have previously been observed in major depressive disorder (96), and these differences have been attributed to somatic complaints, such as dizziness, that are frequently endorsed by patients with depression. PTSD and major depressive disorder are highly comorbid (97, 98). Therefore, smaller lobule X volume may be unique to patients with prominent depressive features and/or a more somatic symptom profile.

Limitations:
This is the largest study of cerebellar volumetry in PTSD to date, however, there are several notable limitations. PTSD is a heterogeneous disorder and is highly comorbid with other psychiatric conditions (e.g., depression, substance use disorders) and environmental exposures (e.g., childhood trauma) that are also linked to alterations in cerebellar structure (72, 77, 79). Employing a mega-analysis in a large multi-cohort consortium dataset enabled us to observe small effect sizes of PTSD on cerebellar volume in our primary analyses, but many sites did not provide diagnostic or item-level data for relevant covariates. Consequently, we were unable to investigate effects of relevant covariates at the same scale. Future studies would benefit from investigating unique and shared phenotypes of PTSD and other psychopathology on the cerebellum to disentangle potential dissociable effects and complex interactions more elegantly. It is also critical for future work to examine how the cerebellum may be uniquely implicated in the dissociative subtype of PTSD. Dissociative symptoms in PTSD are linked to alterations within the midbrain that facilitate passive, rather than active, defensive responses (99, 100); observed differences in cerebellar functional activation and connectivity related to the dissociative subtype of PTSD (65, 67, 101, 102) may be mediated by the prominent neural pathways between the

cerebellum and midbrain. The current study was also focused solely on cerebellar volumetric differences in PTSD. Multiple studies have observed disrupted cerebellar activity both at rest (44, 65, 102) and during trauma-relevant tasks (47, 67, 81, 103) in patients with PTSD. Future work would benefit from improved localization of both functional and structural changes in the cerebellum that may be present in PTSD. Lastly, the current study is cross-sectional in nature; future longitudinal research will be imperative to better understand whether cerebellum volume confers risk for PTSD or changes as a function of the disorder.

Conclusion:
In a sample of over 4000 individuals from the ENIGMA-PGC PTSD Consortium, cerebellum volume was significantly smaller in patients with PTSD compared to pooled groups of trauma-exposed and trauma naïve controls. Specific subregional volume reductions in the vermis and posterior cerebellum (crus II and lobule VIIB) align with previous work demonstrating their involvement in cognitive and affective functions relevant to PTSD, such as fear learning and regulation. Overall, these findings argue for a critical role of the cerebellum in the pathophysiology of PTSD, bolstering support for the region's contributions to processes beyond vestibulomotor function.

References

1. Kilpatrick DG, Resnick HS, Milanak ME, Miller MW, Keyes KM, Friedman MJ (2013): National estimates of exposure to traumatic events and PTSD prevalence using DSM-IV and DSM-5 criteria. *J Trauma Stress*. 26:537-547.
2. Association AP (2013): *Diagnostic and statistical manual of mental disorders (5th ed)*.
3. Harnett NG, Goodman AM, Knight DC (2020): PTSD-related neuroimaging abnormalities in brain function, structure, and biochemistry. *Exp Neurol*. 330:113331.
4. Hayes JP, Hayes SM, Mikedis AM (2012): Quantitative meta-analysis of neural activity in posttraumatic stress disorder. *Biol Mood Anxiety Disord*. 2:9.
5. Karl A, Schaefer M, Malta LS, Dorfel D, Rohleder N, Werner A (2006): A meta-analysis of structural brain abnormalities in PTSD. *Neurosci Biobehav Rev*. 30:1004-1031.
6. Kitayama N, Vaccarino V, Kutner M, Weiss P, Bremner JD (2005): Magnetic resonance imaging (MRI) measurement of hippocampal volume in posttraumatic stress disorder: a meta-analysis. *J Affect Disord*. 88:79-86.
7. Logue MW, van Rooij SJH, Dennis EL, Davis SL, Hayes JP, Stevens JS, et al. (2018): Smaller Hippocampal Volume in Posttraumatic Stress Disorder: A Multisite ENIGMA-PGC Study: Subcortical Volumetry Results From Posttraumatic Stress Disorder Consortia. *Biol Psychiatry*. 83:244-253.
8. Woon FL, Sood S, Hedges DW (2010): Hippocampal volume deficits associated with exposure to psychological trauma and posttraumatic stress disorder in adults: a meta-analysis. *Prog Neuropsychopharmacol Biol Psychiatry*. 34:1181-1188.
9. O'Doherty DC, Chitty KM, Saddiqui S, Bennett MR, Lagopoulos J (2015): A systematic review and meta-analysis of magnetic resonance imaging measurement of structural volumes in posttraumatic stress disorder. *Psychiatry Res*. 232:1-33.
10. Morey RA, Haswell CC, Hooper SR, De Bellis MD (2016): Amygdala, Hippocampus, and Ventral Medial Prefrontal Cortex Volumes Differ in Maltreated Youth with and without Chronic Posttraumatic Stress Disorder. *Neuropsychopharmacology*. 41:791-801.
11. Kuhn S, Gallinat J (2013): Gray matter correlates of posttraumatic stress disorder: a quantitative meta-analysis. *Biol Psychiatry*. 73:70-74.
12. Keding TJ, Herringa RJ (2015): Abnormal structure of fear circuitry in pediatric post-traumatic stress disorder. *Neuropsychopharmacology*. 40:537-545.
13. Morey RA, Gold AL, LaBar KS, Beall SK, Brown VM, Haswell CC, et al. (2012): Amygdala volume changes in posttraumatic stress disorder in a large case-controlled veterans group. *Arch Gen Psychiatry*. 69:1169-1178.
14. Rogers MA, Yamasue H, Abe O, Yamada H, Ohtani T, Iwanami A, et al. (2009): Smaller amygdala volume and reduced anterior cingulate gray matter density associated with history of post-traumatic stress disorder. *Psychiatry Res*. 174:210-216.
15. Veer IM, Oei NY, van Buchem MA, Spinhoven P, Elzinga BM, Rombouts SA (2015): Evidence for smaller right amygdala volumes in posttraumatic stress disorder following childhood trauma. *Psychiatry Res*. 233:436-442.
16. Herringa R, Phillips M, Almeida J, Insana S, Germain A (2012): Post-traumatic stress symptoms correlate with smaller subgenual cingulate, caudate, and insula volumes in unmedicated combat veterans. *Psychiatry Res*. 203:139-145.
17. Chen S, Xia W, Li L, Liu J, He Z, Zhang Z, et al. (2006): Gray matter density reduction in the insula in fire survivors with posttraumatic stress disorder: a voxel-based morphometric study. *Psychiatry Res*. 146:65-72.
18. Meng Y, Qiu C, Zhu H, Lama S, Lui S, Gong Q, et al. (2014): Anatomical deficits in adult posttraumatic stress disorder: a meta-analysis of voxel-based morphometry studies. *Behav Brain Res*. 270:307-315.
19. Woodward SH, Kaloupek DG, Streeter CC, Martinez C, Schaer M, Eliez S (2006): Decreased anterior cingulate volume in combat-related PTSD. *Biol Psychiatry*. 59:582-587.
20. Kitayama N, Quinn S, Bremner JD (2006): Smaller volume of anterior cingulate cortex in abuse-related posttraumatic stress disorder. *J Affect Disord*. 90:171-174.

21. Shin LM, Liberzon I (2010): The neurocircuitry of fear, stress, and anxiety disorders. *Neuropsychopharmacology*. 35:169-191.
22. Rauch SL, Shin LM, Phelps EA (2006): Neurocircuitry models of posttraumatic stress disorder and extinction: human neuroimaging research--past, present, and future. *Biol Psychiatry*. 60:376-382.
23. Adamaszek M, D'Agata F, Ferrucci R, Habas C, Keulen S, Kirkby KC, et al. (2017): Consensus Paper: Cerebellum and Emotion. *Cerebellum*. 16:552-576.
24. Schmahmann JD (2019): The cerebellum and cognition. *Neurosci Lett*. 688:62-75.
25. Schmahmann JD, Caplan D (2006): Cognition, emotion and the cerebellum. *Brain*. 129:290-292.
26. Timmann D, Drepper J, Frings M, Maschke M, Richter S, Gerwig M, et al. (2010): The human cerebellum contributes to motor, emotional and cognitive associative learning. A review. *Cortex*. 46:845-857.
27. Balsters JH, Cussans E, Diedrichsen J, Phillips KA, Preuss TM, Rilling JK, et al. (2010): Evolution of the cerebellar cortex: the selective expansion of prefrontal-projecting cerebellar lobules. *Neuroimage*. 49:2045-2052.
28. Barton RA, Venditti C (2014): Rapid evolution of the cerebellum in humans and other great apes. *Curr Biol*. 24:2440-2444.
29. Sereno MI, Diedrichsen J, Tachrount M, Testa-Silva G, d'Arceuil H, De Zeeuw C (2020): The human cerebellum has almost 80% of the surface area of the neocortex. *Proc Natl Acad Sci U S A*. 117:19538-19543.
30. Solov'ev SV (2006): The weight and linear dimensions of the human cerebellum. *Neurosci Behav Physiol*. 36:479-481.
31. Azevedo FA, Carvalho LR, Grinberg LT, Farfel JM, Ferretti RE, Leite RE, et al. (2009): Equal numbers of neuronal and nonneuronal cells make the human brain an isometrically scaled-up primate brain. *J Comp Neurol*. 513:532-541.
32. Bernard JA, Seidler RD, Hassevoort KM, Benson BL, Welsh RC, Wiggins JL, et al. (2012): Resting state cortico-cerebellar functional connectivity networks: a comparison of anatomical and self-organizing map approaches. *Front Neuroanat*. 6:31.
33. Buckner RL, Krienen FM, Castellanos A, Diaz JC, Yeo BT (2011): The organization of the human cerebellum estimated by intrinsic functional connectivity. *J Neurophysiol*. 106:2322-2345.
34. Schmahmann JD (2021): Emotional disorders and the cerebellum: Neurobiological substrates, neuropsychiatry, and therapeutic implications. *Handb Clin Neurol*. 183:109-154.
35. Moreno-Rius J (2019): The cerebellum under stress. *Front Neuroendocrinol*. 54:100774.
36. Carletto S, Borsato T (2017): Neurobiological correlates of post-traumatic stress disorder: a focus on cerebellum role. *European Journal of Trauma & Dissociation*. 1:153-157.
37. Blithikioti C, Nuno L, Guell X, Pascual-Diaz S, Gual A, Balcells-Olivero M, et al. (2022): The cerebellum and psychological trauma: A systematic review of neuroimaging studies. *Neurobiol Stress*. 17:100429.
38. Ernst TM, Brol AE, Gratz M, Ritter C, Bingel U, Schlamann M, et al. (2019): The cerebellum is involved in processing of predictions and prediction errors in a fear conditioning paradigm. *Elife*. 8.
39. Frontera JL, Baba Aissa H, Sala RW, Mailhes-Hamon C, Georgescu IA, Lena C, et al. (2020): Bidirectional control of fear memories by cerebellar neurons projecting to the ventrolateral periaqueductal grey. *Nat Commun*. 11:5207.
40. Lange I, Kasanova Z, Goossens L, Leibold N, De Zeeuw CI, van Amelsvoort T, et al. (2015): The anatomy of fear learning in the cerebellum: A systematic meta-analysis. *Neurosci Biobehav Rev*. 59:83-91.
41. Milad MR, Quirk GJ (2012): Fear extinction as a model for translational neuroscience: ten years of progress. *Annu Rev Psychol*. 63:129-151.
42. Sevenster D, Visser RM, D'Hooge R (2018): A translational perspective on neural circuits of fear extinction: Current promises and challenges. *Neurobiol Learn Mem*. 155:113-126.
43. Baldacara L, Jackowski AP, Schoedl A, Pupo M, Andreoli SB, Mello MF, et al. (2011): Reduced cerebellar left hemisphere and vermal volume in adults with PTSD from a community sample. *J Psychiatr Res*. 45:1627-1633.

44. Holmes SE, Scheinost D, DellaGioia N, Davis MT, Matuskey D, Pietrzak RH, et al. (2018): Cerebellar and prefrontal cortical alterations in PTSD: structural and functional evidence. *Chronic Stress (Thousand Oaks)*. 2.
45. De Bellis MD, Kuchibhatla M (2006): Cerebellar volumes in pediatric maltreatment-related posttraumatic stress disorder. *Biol Psychiatry*. 60:697-703.
46. Carrion VG, Weems CF, Watson C, Eliez S, Menon V, Reiss AL (2009): Converging evidence for abnormalities of the prefrontal cortex and evaluation of midsagittal structures in pediatric posttraumatic stress disorder: an MRI study. *Psychiatry Res*. 172:226-234.
47. Belleau EL, Ehret LE, Hanson JL, Brasel KJ, Larson CL, deRoon-Cassini TA (2020): Amygdala functional connectivity in the acute aftermath of trauma prospectively predicts severity of posttraumatic stress symptoms. *Neurobiol Stress*. 12:100217.
48. Pannu Hayes J, Labar KS, Petty CM, McCarthy G, Morey RA (2009): Alterations in the neural circuitry for emotion and attention associated with posttraumatic stress symptomatology. *Psychiatry Res*. 172:7-15.
49. Koch SB, van Zuiden M, Nawijn L, Frijling JL, Veltman DJ, Olff M (2016): Aberrant Resting-State Brain Activity in Posttraumatic Stress Disorder: A Meta-Analysis and Systematic Review. *Depress Anxiety*. 33:592-605.
50. Wang T, Liu J, Zhang J, Zhan W, Li L, Wu M, et al. (2016): Altered resting-state functional activity in posttraumatic stress disorder: A quantitative meta-analysis. *Sci Rep*. 6:27131.
51. Fennema-Notestine C, Stein MB, Kennedy CM, Archibald SL, Jernigan TL (2002): Brain morphometry in female victims of intimate partner violence with and without posttraumatic stress disorder. *Biol Psychiatry*. 52:1089-1101.
52. Levitt JJ, Chen QC, May FS, Gilbertson MW, Shenton ME, Pitman RK (2006): Volume of cerebellar vermis in monozygotic twins discordant for combat exposure: lack of relationship to post-traumatic stress disorder. *Psychiatry Res*. 148:143-149.
53. Clouston SAP, Kritikos M, Huang C, Kuan PF, Vaska P, Pellecchia AC, et al. (2022): Reduced cerebellar cortical thickness in World Trade Center responders with cognitive impairment. *Transl Psychiatry*. 12:107.
54. Singh R (2020): *Cerebellum: its anatomy, functions and diseases*.
55. Oscarsson O (1965): Functional Organization of the Spino- and Cuneocerebellar Tracts. *Physiol Rev*. 45:495-522.
56. Stoodley CJ, Schmahmann JD (2009): Functional topography in the human cerebellum: a meta-analysis of neuroimaging studies. *Neuroimage*. 44:489-501.
57. Schmahmann JD, Pandya DN (1995): Prefrontal cortex projections to the basilar pons in rhesus monkey: implications for the cerebellar contribution to higher function. *Neurosci Lett*. 199:175-178.
58. Schmahmann JD, Pandya DN (1997): The cerebrocerebellar system. *Int Rev Neurobiol*. 41:31-60.
59. Marvel CL, Desmond JE (2010): Functional topography of the cerebellum in verbal working memory. *Neuropsychol Rev*. 20:271-279.
60. Moulton EA, Elman I, Pendse G, Schmahmann J, Becerra L, Borsook D (2011): Aversion-related circuitry in the cerebellum: responses to noxious heat and unpleasant images. *J Neurosci*. 31:3795-3804.
61. Schutter DJ, van Honk J (2005): The cerebellum on the rise in human emotion. *Cerebellum*. 4:290-294.
62. Pierce JE, Thomasson M, Voruz P, Selosse G, Peron J (2022): Explicit and Implicit Emotion Processing in the Cerebellum: A Meta-analysis and Systematic Review. *Cerebellum*.
63. Canu E, Calderaro D, Castelnovo V, Basaia S, Magno MA, Riva N, et al. (2022): Resting state functional brain networks associated with emotion processing in frontotemporal lobar degeneration. *Mol Psychiatry*.
64. Schienle A, Scharmuller W (2013): Cerebellar activity and connectivity during the experience of disgust and happiness. *Neuroscience*. 246:375-381.
65. Rabellino D, Densmore M, Theberge J, McKinnon MC, Lanius RA (2018): The cerebellum after trauma: Resting-state functional connectivity of the cerebellum in posttraumatic stress disorder and its dissociative subtype. *Hum Brain Mapp*. 39:3354-3374.

66. Naegeli C, Zeffiro T, Piccirelli M, Jaillard A, Weilenmann A, Hassanpour K, et al. (2018): Locus Coeruleus Activity Mediates Hyperresponsiveness in Posttraumatic Stress Disorder. *Biol Psychiatry*. 83:254-262.
67. Rabellino D, Densmore M, Frewen PA, Theberge J, Lanius RA (2016): The innate alarm circuit in post-traumatic stress disorder: Conscious and subconscious processing of fear- and trauma-related cues. *Psychiatry Res Neuroimaging*. 248:142-150.
68. Sui SG, Zhang Y, Wu MX, Xu JM, Duan L, Weng XC, et al. (2010): Abnormal cerebellum density in victims of rape with post-traumatic stress disorder: voxel-based analysis of magnetic resonance imaging investigation. *Asia Pacific Psychiatry*. 2:129-135.
69. Han S, Carass A, He Y, Prince JL (2020): Automatic cerebellum anatomical parcellation using U-Net with locally constrained optimization. *Neuroimage*. 218:116819.
70. Bates D, Mächler M, Bolker B, Walker S (2015): Fitting linear mixed-effects models using lme4. *Journal of Statistical Software*. 67:1-48.
71. Benjamini Y, Hochberg Y (1995): Controlling the false discovery rate: a practical and powerful approach to multiple testing. *Journal of the Royal Statistical Society, Series B*. 57:289-300.
72. Lupo M, Siciliano L, Leggio M (2019): From cerebellar alterations to mood disorders: A systematic review. *Neurosci Biobehav Rev*. 103:21-28.
73. Peng J, Liu J, Nie B, Li Y, Shan B, Wang G, et al. (2011): Cerebral and cerebellar gray matter reduction in first-episode patients with major depressive disorder: a voxel-based morphometry study. *Eur J Radiol*. 80:395-399.
74. Miquel M, Vazquez-Sanroman D, Carbo-Gas M, Gil-Miravet I, Sanchis-Segura C, Carulli D, et al. (2016): Have we been ignoring the elephant in the room? Seven arguments for considering the cerebellum as part of addiction circuitry. *Neurosci Biobehav Rev*. 60:1-11.
75. Segobin SH, Chetelat G, Le Berre AP, Lannuzel C, Boudehent C, Vabret F, et al. (2014): Relationship between brain volumetric changes and interim drinking at six months in alcohol-dependent patients. *Alcohol Clin Exp Res*. 38:739-748.
76. Clausen AN, Aupperle RL, Yeh HW, Waller D, Payne J, Kuplicki R, et al. (2019): Machine Learning Analysis of the Relationships Between Gray Matter Volume and Childhood Trauma in a Transdiagnostic Community-Based Sample. *Biol Psychiatry Cogn Neurosci Neuroimaging*. 4:734-742.
77. Teicher MH, Samson JA (2016): Annual Research Review: Enduring neurobiological effects of childhood abuse and neglect. *J Child Psychol Psychiatry*. 57:241-266.
78. Bernstein DP, Fink L (1998): *Childhood Trauma Questionnaire: a retrospective self-report manual*. San Antonio, TX: The Psychological Corporation.
79. Phillips JR, Hewedi DH, Eissa AM, Moustafa AA (2015): The cerebellum and psychiatric disorders. *Front Public Health*. 3:66.
80. Yin Y, Li L, Jin C, Hu X, Duan L, Eyler LT, et al. (2011): Abnormal baseline brain activity in posttraumatic stress disorder: a resting-state functional magnetic resonance imaging study. *Neurosci Lett*. 498:185-189.
81. Quide Y, Clery H, Andersson F, Descriaud C, Saint-Martin P, Barantin L, et al. (2018): Neurocognitive, emotional and neuroendocrine correlates of exposure to sexual assault in women. *J Psychiatry Neurosci*. 43:318-326.
82. Abdallah CG, Averill CL, Ramage AE, Averill LA, Goktas S, Nemati S, et al. (2019): Salience Network Disruption in U.S. Army Soldiers With Posttraumatic Stress Disorder. *Chronic Stress (Thousand Oaks)*. 3.
83. Habas C, Kamdar N, Nguyen D, Prater K, Beckmann CF, Menon V, et al. (2009): Distinct cerebellar contributions to intrinsic connectivity networks. *J Neurosci*. 29:8586-8594.
84. Guell X, Schmahmann JD, Gabrieli J, Ghosh SS (2018): Functional gradients of the cerebellum. *Elife*. 7.
85. Ke J, Zhang L, Qi R, Xu Q, Li W, Hou C, et al. (2015): Altered blood oxygen level-dependent signal variability in chronic post-traumatic stress disorder during symptom provocation. *Neuropsychiatr Dis Treat*. 11:1805-1815.
86. Claassen J, Labrenz F, Ernst TM, Icenhour A, Langhorst J, Forsting M, et al. (2017): Altered Cerebellar Activity in Visceral Pain-Related Fear Conditioning in Irritable Bowel Syndrome. *Cerebellum*. 16:508-517.

87. Frings M, Maschke M, Erichsen M, Jentzen W, Muller SP, Kolb FP, et al. (2002): Involvement of the human cerebellum in fear-conditioned potentiation of the acoustic startle response: a PET study. *Neuroreport*. 13:1275-1278.
88. Sacchetti B, Baldi E, Lorenzini CA, Bucherelli C (2002): Cerebellar role in fear-conditioning consolidation. *Proc Natl Acad Sci U S A*. 99:8406-8411.
89. Batsikadze G, Diekmann N, Ernst TM, Klein M, Maderwald S, Deuschl C, et al. (2022): The cerebellum contributes to context-effects during fear extinction learning: A 7T fMRI study. *Neuroimage*. 253:119080.
90. Fullana MA, Albajes-Eizagirre A, Soriano-Mas C, Vervliet B, Cardoner N, Benet O, et al. (2018): Fear extinction in the human brain: A meta-analysis of fMRI studies in healthy participants. *Neurosci Biobehav Rev*. 88:16-25.
91. Utz A, Thurling M, Ernst TM, Hermann A, Stark R, Wolf OT, et al. (2015): Cerebellar vermis contributes to the extinction of conditioned fear. *Neurosci Lett*. 604:173-177.
92. Habas C, Manto M (2018): Probing the neuroanatomy of the cerebellum using tractography. *Handb Clin Neurol*. 154:235-249.
93. Koutsikou S, Crook JJ, Earl EV, Leith JL, Watson TC, Lumb BM, et al. (2014): Neural substrates underlying fear-evoked freezing: the periaqueductal grey-cerebellar link. *J Physiol*. 592:2197-2213.
94. Thome J, Densmore M, Frewen PA, McKinnon MC, Theberge J, Nicholson AA, et al. (2017): Desynchronization of autonomic response and central autonomic network connectivity in posttraumatic stress disorder. *Hum Brain Mapp*. 38:27-40.
95. Argyropoulos GPD, van Dun K, Adamaszek M, Leggio M, Manto M, Masciullo M, et al. (2020): The Cerebellar Cognitive Affective/Schmahmann Syndrome: a Task Force Paper. *Cerebellum*. 19:102-125.
96. Xu LY, Xu FC, Liu C, Ji YF, Wu JM, Wang Y, et al. (2017): Relationship between cerebellar structure and emotional memory in depression. *Brain Behav*. 7:e00738.
97. O'Donnell ML, Creamer M, Pattison P (2004): Posttraumatic stress disorder and depression following trauma: understanding comorbidity. *Am J Psychiatry*. 161:1390-1396.
98. Brady KT, Killeen TK, Brewerton T, Lucerini S (2000): Comorbidity of psychiatric disorders and posttraumatic stress disorder. *J Clin Psychiatry*. 61 Suppl 7:22-32.
99. Harricharan S, Rabellino D, Frewen PA, Densmore M, Theberge J, McKinnon MC, et al. (2016): fMRI functional connectivity of the periaqueductal gray in PTSD and its dissociative subtype. *Brain Behav*. 6:e00579.
100. Nicholson AA, Friston KJ, Zeidman P, Harricharan S, McKinnon MC, Densmore M, et al. (2017): Dynamic causal modeling in PTSD and its dissociative subtype: Bottom-up versus top-down processing within fear and emotion regulation circuitry. *Hum Brain Mapp*. 38:5551-5561.
101. Nicholson AA, Densmore M, Frewen PA, Theberge J, Neufeld RW, McKinnon MC, et al. (2015): The Dissociative Subtype of Posttraumatic Stress Disorder: Unique Resting-State Functional Connectivity of Basolateral and Centromedial Amygdala Complexes. *Neuropsychopharmacology*. 40:2317-2326.
102. Lebois LAM, Harnett NG, van Rooij SJH, Ely TD, Jovanovic T, Bruce SE, et al. (2022): Persistent Dissociation and Its Neural Correlates in Predicting Outcomes After Trauma Exposure. *Am J Psychiatry*. 179:661-672.
103. Terpou BA, Densmore M, Thome J, Frewen P, McKinnon MC, Lanius RA (2019): The Innate Alarm System and Subliminal Threat Presentation in Posttraumatic Stress Disorder: Neuroimaging of the Midbrain and Cerebellum. *Chronic Stress (Thousand Oaks)*. 3:2470547018821496.